Journal of Medical Surgical and Allied Sciences
ISSN (Online): 3048-541X
Case Report

Acute small bowel obstruction secondary to a pickled mango phytobezoar at an occult stricture

Mohamad Nurfaiz Bin Mohd Nazri*, Viknesh A/L Subramaniam

Department of Surgery, Hospital Tanjong Karang , Selangor, Malaysia.

*Correspondence
Mohamad Nurfaiz Mohd Nazri
faizkmb92@gmail.com

Creative Commons Attribution 4.0 International (CC BY 4.0) Licence.

Volume: 4, Issue: 2, Pages: 1-5
DOI: https://doi.org/10.37446/jmedsurg/cr/4.2.2026.1-5
Received: 27 July 2026 / Accepted: 13 September 2026 / Published: 25 November 2026

Background: Phytobezoars represent a rare but clinically significant cause of mechanical small bowel obstruction (SBO), accounting for a small fraction of cases globally. While obstructions caused by raw fruit fibers are occasionally reported, those secondary to unpeeled, cured pickled mangoes are exceptionally rare. This case highlights a unique presentation where regional dietary habits coincided with an underlying structural bowel pathology.

Case Presentation: A 45-year-old male with a virgin abdomen presented with a two-day history of epigastric pain and vomiting, progressing to absolute constipation. He reported consuming unpeeled mango pickles prior to symptom onset. Contrast-enhanced computed tomography (CECT) of the abdomen revealed a dilated proximal small bowel featuring the "small bowel feces sign," terminating abruptly with distal collapse. Emergency exploratory laparotomy identified an organic stricture 100 cm proximal to the ileocecal junction, accompanied by an impacted, hard intraluminal mass immediately proximal to the stenotic segment. A segmental wedge resection of the strictured bowel with primary anastomosis was performed. Bench enterotomy of the resected specimen confirmed the obstructing mass to be an intact, fibrous bolus of unpeeled pickled mango.

Conclusion: This case demonstrates that unpeeled pickled mango can precipitate acute mechanical SBO, particularly when it encounters a localized small bowel narrowing. Surgeons should maintain a high index of suspicion for phytobezoars in virgin abdomens, utilizing targeted dietary histories and CECT findings to guide operative strategy.

Keywords: *phytobezoar, pickled mango, small bowel obstruction, small bowel feces sign, intestinal stricture*

Introduction

Mechanical small bowel obstruction (SBO) is a ubiquitous surgical emergency, most frequently attributed to postoperative adhesions, incarcerated hernias, or intestinal malignancies. Phytobezoars-compacted gastrointestinal masses composed of indigestible plant fibers, cellulose, and lignin-are a distinctly uncommon etiology, accounting for less than 4% of all mechanical SBO cases globally (Wang et al., 2021). While the stomach serves as the primary site of bezoar formation, unfragmented fibrous boluses that escape the pylorus can migrate distally. They typically lodge in the mid-to-distal ileum, where the intestinal lumen naturally narrows and peristalsis weakens (Paschos & Chatzigeorgiadis, 2019). Mangoes (*Mangifera indica*), a popular fruit in ASEAN countries and Malaysia specifically, are highly fibrous and rich in insoluble cellulose (Hulf & Ben-David, 2023). When prepared as pickles, the curing process alters the physical characteristics of the rind and pulp. It is hypothesized that this process renders the unpeeled fibers leathery and cohesive, making them

potentially more resistant to standard gastric enzymatic degradation (Islam et al., 2018). The novelty of this report lies in its highly atypical etiology and presentation. We present the rare case of a 45-year-old male with no prior surgical history who developed an acute, high-grade mechanical SBO. The obstruction required a segmental wedge resection due to the impaction of an unpeeled pickled mango phytobezoar at the site of an occult, localized small bowel stricture.

Case presentation

A 45-year-old male with no known medical illnesses and no history of abdominal surgery presented to the emergency department. He reported a two-day history of progressive epigastric pain and persistent vomiting. This was accompanied by a one-day history of absolute constipation, characterized by an inability to pass both feces and flatus. On targeted dietary anamnesis, the patient recalled consuming a substantial amount of unpeeled mango pickles shortly before the onset of his symptoms. Clinical evaluation revealed stable vital signs. Cardiovascular examination demonstrated a dual rhythm with no murmurs, and the lung fields were clear on auscultation. Abdominal examination revealed a soft but significantly distended abdomen, with marked tenderness localized to the epigastric and umbilical regions. There was no clinical evidence of involuntary guarding or rigidity. Bowel sounds were present, and no palpable hernias were identified. Laboratory investigations revealed a mild leukocytosis (12.1 x 10^9/L), while serum electrolytes, renal function, and liver function tests were within normal limits. Initial plain film radiography via chest X-ray showed no evidence of pneumoperitoneum. An abdominal X-ray (AXR) demonstrated centrally located, dilated loops of small bowel with prominent air-fluid levels, confirming a mechanical obstruction. To delineate the precise etiology and transition point, a Contrast-Enhanced Computed Tomography (CECT) of the abdomen was performed. The CECT demonstrated a highly dilated afferent small bowel loop exhibiting the "small bowel feces sign" **(**Figures 1 and 2**)**-an intraluminal accumulation of gas bubbles mixed with particulate matter resembling colonic feces, indicative of intestinal stasis (Khaled et al., 2018). This impacted mass terminated abruptly at a transition point, followed by complete collapse of the efferent loop. The distal ileum and large bowel were entirely collapsed. There was no radiological evidence of an intrinsic bowel mass, bowel wall thickening, pneumatosis intestinalis, portal venous gas, or pneumoperitoneum (Lappas et al., 2001).

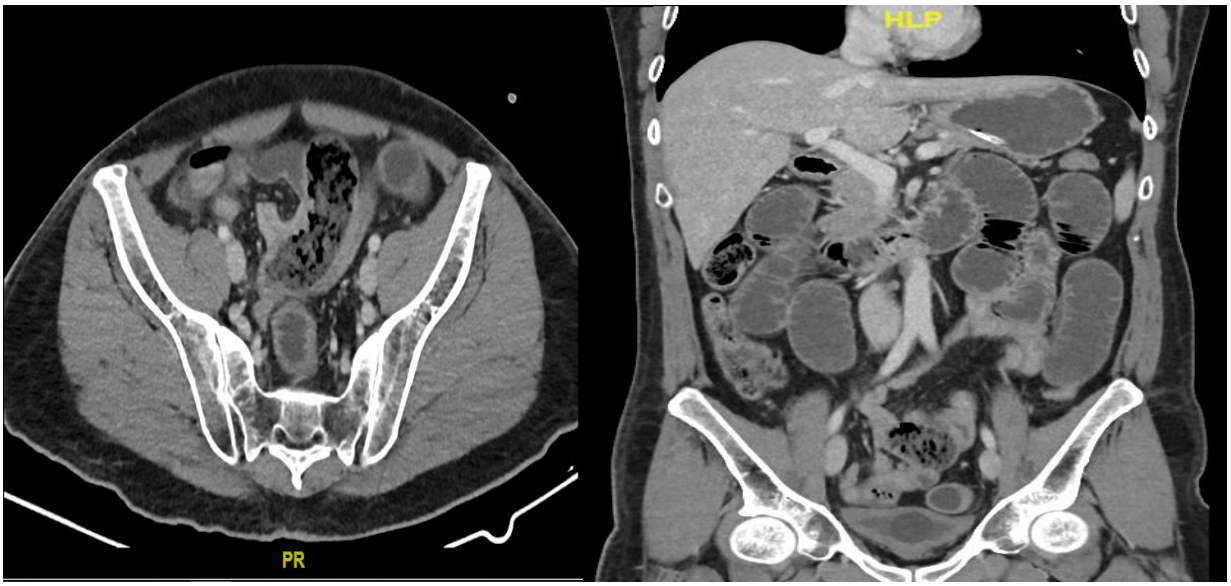

Figures 1 and 2. CECT Images in axial and coronal views. The arrows indicate the "small bowel feces sign" within the dilated afferent loop, located immediately proximal to the transition zone. Given the complete mechanical nature of the obstruction and the progressive clinical picture, the patient underwent an emergency exploratory laparotomy.

Upon accessing the peritoneal cavity, reactive free fluid and localized purulent-appearing exudate were noted within the pelvis, suggesting a localized inflammatory response secondary to high intraluminal pressure and stasis. A meticulous bowel run identified a focal, organic small bowel stricture located exactly 100 cm proximal to the ileocecal junction. Proximal to this strictured segment, the small bowel loops were profoundly dilated and congested; distally, the loops were entirely collapsed. Immediately proximal to the stricture site, a hard, unyielding intraluminal mass was palpated (Figures 3 and 4) (Taha et al., 2019). Systematic inspection of the liver, stomach, spleen, and the remaining bowel revealed no abnormalities.

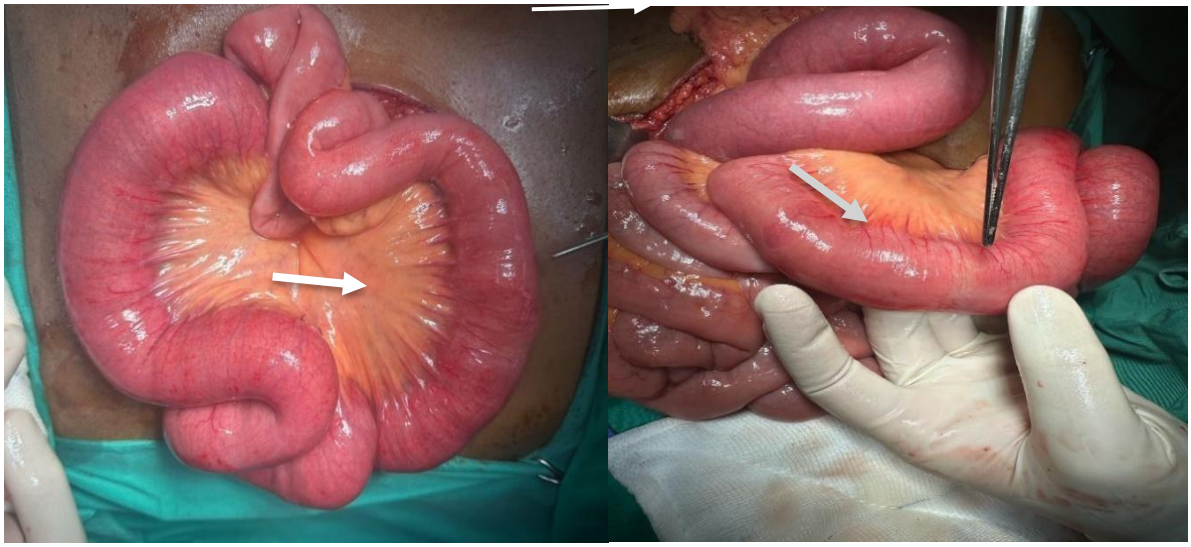

Figures 3 and 4. Intraoperative photographs demonstrating the focal stenotic segment of the small bowel (arrows) containing the impacted bezoar, with notable proximal dilatation.

Due to the presence of the rigid organic stricture, a simple enterotomy with manual fragmentation (milking) of the mass was deemed structurally hazardous. Instead, a segmental wedge resection of the stricture site was executed, inclusive of the impacted mass, followed by a primary hand-sewn anastomosis to restore intestinal continuity (Jang et al., 2024). On bench examination of the resected specimen, a longitudinal enterotomy over the impacted site revealed a dense, fibrous, unaltered mass of unpeeled mango pickles, which had occluded the stenosed lumen (Figure 5).



Figure 5. The resected wedge segment of the small bowel following bench enterotomy, displaying the extracted unpeeled mango phytobezoar and the adjacent strictured mucosal wall.

The patient's postoperative course was unremarkable. Intestinal motility returned on postoperative day 3, marked by the passage of flatus and a bowel movement. He was gradually transitioned from a clear liquid diet to a low-residue soft diet (Angulo et al., 2026). He was discharged in stable condition with explicit dietary counseling regarding the importance of meticulous mastication and avoiding the consumption of unpeeled, highly fibrous fruits (López-Jaime et al., 2024).

Detailed histopathological examination of the resected small bowel segment demonstrated severe focal mucosal ulceration, acute inflammatory cell infiltration, and transmural edema consistent with an acute reaction to the impaction. Importantly, there was no histological evidence of malignancy or chronic granulomatous diseases to explain the stricture.

Discussion

Mechanical SBO secondary to a phytobezoar is a rare clinical entity (Manning et al., 2015; Wang et al., 2021). While dietary impactions involving persimmons (diospyrobezoars) are well-documented, mango-induced phytobezoars remain highly atypical (Taha et al., 2019; Hulf & Ben-David, 2023). This case presents a unique convergence of factors: a patient with a virgin abdomen presenting with an acute impaction of unpeeled, pickled mango at the site of a localized small bowel stricture (Manning et al., 2015). Given the histopathological findings of acute inflammation without malignancy or granulomas, the stricture may have been an occult, pre-existing benign narrowing, or alternatively, a rapid fibrotic and edematous reaction triggered by the impaction itself. The pathophysiology of this specific bezoar formation is likely related to the physical and chemical properties of the fruit. Mango rinds and pulpy fibers possess high concentrations of insoluble cellulose, hemicellulose, and lignin (Hulf & Ben-David, 2023). The pickling process-involving curing in brine and organic acids-is hypothesized to dehydrate the plant tissues and cross-link structural fibers (Islam et al., 2018). This may transform the unpeeled mango into a cohesive bolus resistant to chemical and enzymatic degradation in the stomach, allowing it to transit the pylorus intact. While the wider caliber of the jejunum typically allows for the passage of such boluses, they often arrest at physiological bottlenecks like the terminal ileum (Yu et al., 2025). In this patient, the bolus encountered an occult stricture 100 cm proximal to the ileocecal valve, which functioned as a mechanical sieve, precipitating a high-grade mechanical obstruction (Hulf & Ben-David, 2023; Yu et al., 2025). Diagnostic workup for suspected SBO relies heavily on CT imaging (Wang et al., 2021; Ai-Jiun & Yong-Sim, 2023). Our patient's CECT revealed the "small bowel feces sign." While this radiological phenomenon is not highly specific to phytobezoars, it is a well-documented indicator of subacute or high-grade mechanical obstruction and chronic intestinal stasis (Khaled et al., 2018). The presence of this sign, coupled with abrupt tapering, guided the decision for prompt surgical exploration. Surgical intervention remains the definitive cornerstone of management when conservative measures fail (Paschos & Chatzigeorgiadis, 2019; Manning et al., 2015). The standard surgical paradigm for an uncomplicated bezoar SBO involves simple longitudinal enterotomy or atraumatic digital fragmentation (Taha et al., 2019). However, attempting to milk a rigid mass through a stenotic segment risks iatrogenic perforation, and a simple enterotomy leaves the organic stricture intact, posing a risk for recurrent SBO (Jang et al., 2024). In this specific case, a segmental wedge resection inclusive of the impacted bezoar was therapeutic for the acute obstruction and addressed the underlying bowel pathology.

Conclusion

An unpeeled pickled mango can evolve into a formidable gastrointestinal foreign body. This case underscores the necessity of considering phytobezoars in the differential diagnosis of non-adhesive small bowel obstructions, even in adult patients with a virgin abdomen. It highlights that a meticulous dietary history can provide diagnostic clues that complement radiological findings of intestinal stasis, such as the small bowel feces sign. Finally, while simple enterotomy is standard for uncomplicated bezoars, segmental or wedge resection may be necessary when an underlying localized stricture is identified as the anatomical trap for the impaction.

Author contribution

Mohamad Nurfaiz: Contributed to Case and Manuscript writing , Viknesh Manuscript writing and proofreading.

Acknowledgment

The authors would like to express their sincerest gratitude to all staff members of the Surgical Department at Hospital Tanjong Karang, Selangor, Malaysia for their assistance and guidance. Special appreciation is extended to the patient and his family members for their trust and cooperation, which made this publication possible.

Funding

NIL.

Conflict of interest

The authors declare no conflict of interest. The manuscript has not been submitted for publication in other journal.

Informed consent

Ethical approval was not required as per Institutional guidelines. Written informed consent was obtained from the patient to participate in the study and for the publication of accompanying images.

AI tool declaration

The authors declare that no AI and associated tools are used for writing scientific content in the article.

References

Ai-Jiun, K., & Yong-Sim, T. (2023). The role of non-contrast CT in the diagnosis of a rare cause of small bowel obstruction due to bezoar. *Malaysian Journal of Medicine and Health Sciences*, *19*(2), 334-336.

Angulo, S. D., Giraldo, Á. M., Sáenz Pinto, A., Vazquez, K. O., Mejía, S., & Rodriguez, M. S. (2026). Beyond usual suspects: phytobezoar in pediatrics a diagnostic challenge case report. *International Journal of Surgery Case Reports*, *138*, 1322-1326. https://doi.org/10.1097/RC9.0000000000000198

Hulf, T., & Ben-David, M. (2023). Small bowel obstruction caused by a mango phytobezoar within a Meckel's diverticulum. *Journal of Surgical Case Reports*, 2023(11), rjad613. https://doi.org/10.1093/jscr/rjad613

Islam, S., Saroop, S., Bheem, V., Harnarayan, P., & Naraynsingh, V. (2018). Mango seed causing acute large bowel obstruction in descending colon-world's first reported case. *International Journal of Surgery Case Reports*, *51*, 125-129. https://doi.org/10.1016/j.ijscr.2018.08.028

Jang, J. O., Choi, C. W., Ryu, D. G., Park, S. B., & Kim, S. J. (2024). Clinical outcomes of patients with gastric phytobezoars: implication of drinking carbonated beverages as a treatment. *Korean Journal of Helicobacter and Upper Gastrointestinal Research, 24*(3), 259-266. https://doi.org/10.7704/kjhugr.2024.0032

Khaled, W., Millet, I., Corno, L., Bouley-Coletta, I., Benadjaoud, M. A., Taourel, P., & Zins, M. (2018). Clinical relevance of the feces sign in small-bowel obstruction due to adhesions depends on its location. *American Journal of Roentgenology*, *210*(1), 78-84. https://doi.org/10.2214/AJR.17.18126

Lappas, J. C., Reyes, B. L., & Maglinte, D. D. (2001). Abdominal radiography findings in small-bowel obstruction: relevance to triage for additional diagnostic imaging. *American Journal of Roentgenology*, *176*(1), 167-174. https://doi.org/10.2214/ajr.176.1.1760167

López-Jaime, C. A., Perzabal-Aviléz, C. T., Ruiz-Cereceres, S. J., & Hernández-Carreón, D. (2024). Induced sepsis and structural complications secondary to intestinal phytobezoars. *Edorium Journal of Surgery*, *2*, 5-9.

Manning, E. P., Vattipally, V., Niazi, M., & Shah, A. (2015). Phytobezoar-induced small bowel obstruction in a young male with virgin abdomen. *Journal of Gastrointestinal & Digestive System*, *5*(2), 266. https://doi.org/10.4172/2161-069X.1000266

Paschos, K. A., & Chatzigeorgiadis, A. (2019). Pathophysiological and clinical aspects of the diagnosis and treatment of bezoars. *Annals of Gastroenterology*, *32*(3), 224-232. https://doi.org/10.20524/aog.2019.0370

Taha, Y., Salman, K., Alrayyes, F., & Alrayyes, S. (2019). An unusual case of phytobezoar-induced small bowel obstruction. *Journal of Surgical Case Reports*, *2019*(11), rjz296. https://doi.org/10.1093/jscr/rjz296

Wang, S., Yang, X., Zheng, Y., & Wu, Y. (2021). Clinical characteristics and indications for surgery for bezoar-induced small bowel obstruction. *Journal of International Medical Research*, *49*(1), 0300060521990118. https://doi.org/10.1177/0300060520979377

Yu, K., Feng, W., Liu, L., Cao, C., & Qiang, G. (2025). Pear phytobezoar as a rare cause of small bowel obstruction: a case report. *Frontiers in Medicine*, *12*, 1620356. https://doi.org/10.3389/fmed.2025.1620356